

# SINAL DE PEMBERTON

**Monitora Ano 2015: Mariana Fernandes Guimarães**

**Disciplina de Semiologia**

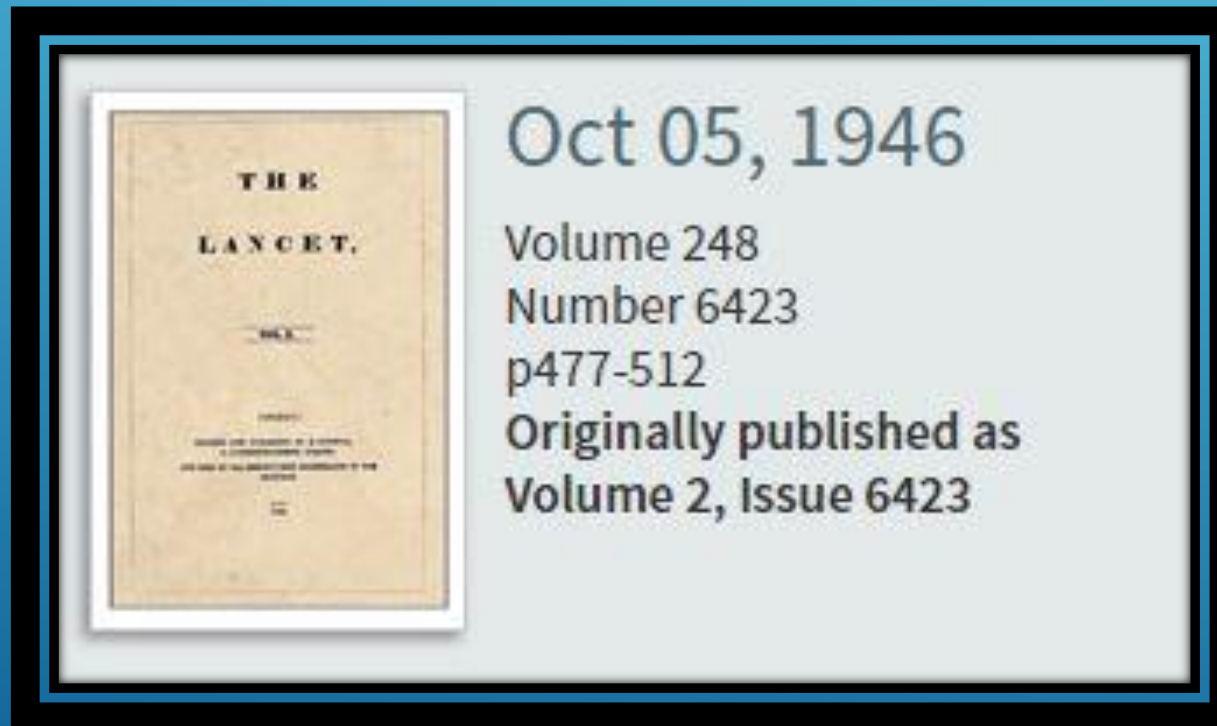
**Universidade Federal Fluminense**

# Hugh Spear Pemberton

Médico inglês (1890 –1956)

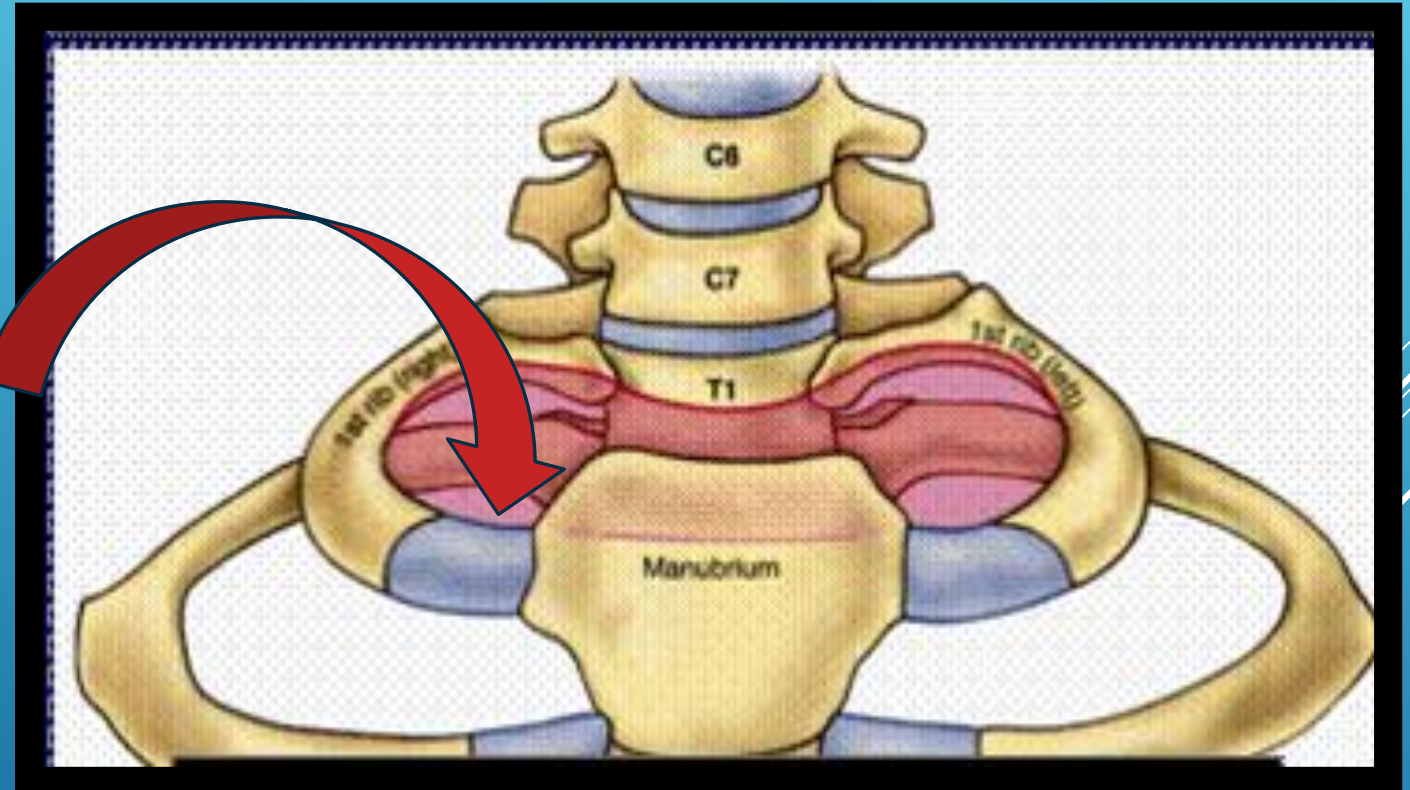
*Artigo original : Sign of submerged goitre.*

The Lancet, London, 1946, 251: 509.



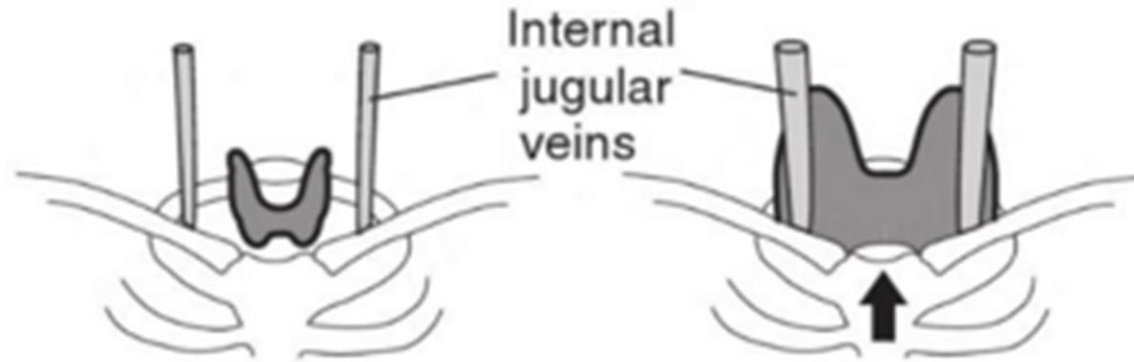
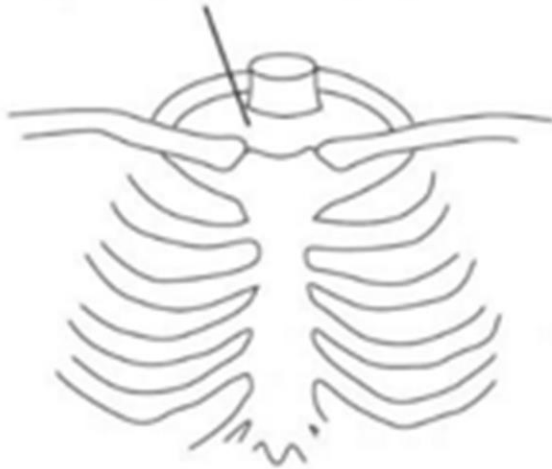# ANATOMIA

Limite lateral- 1<sup>a</sup> arco costal  
Limite anterior- manúbrio  
Limite posterior- T1



# ANATOMIA

Thoracic inlet  
("neck of bottle")



Normal thyroid:  
too small to obstruct  
thoracic inlet

Substernal goiter:  
Elevating arms pulls  
thoracic inlet ("neck of bottle")  
up into goiter ("cork")

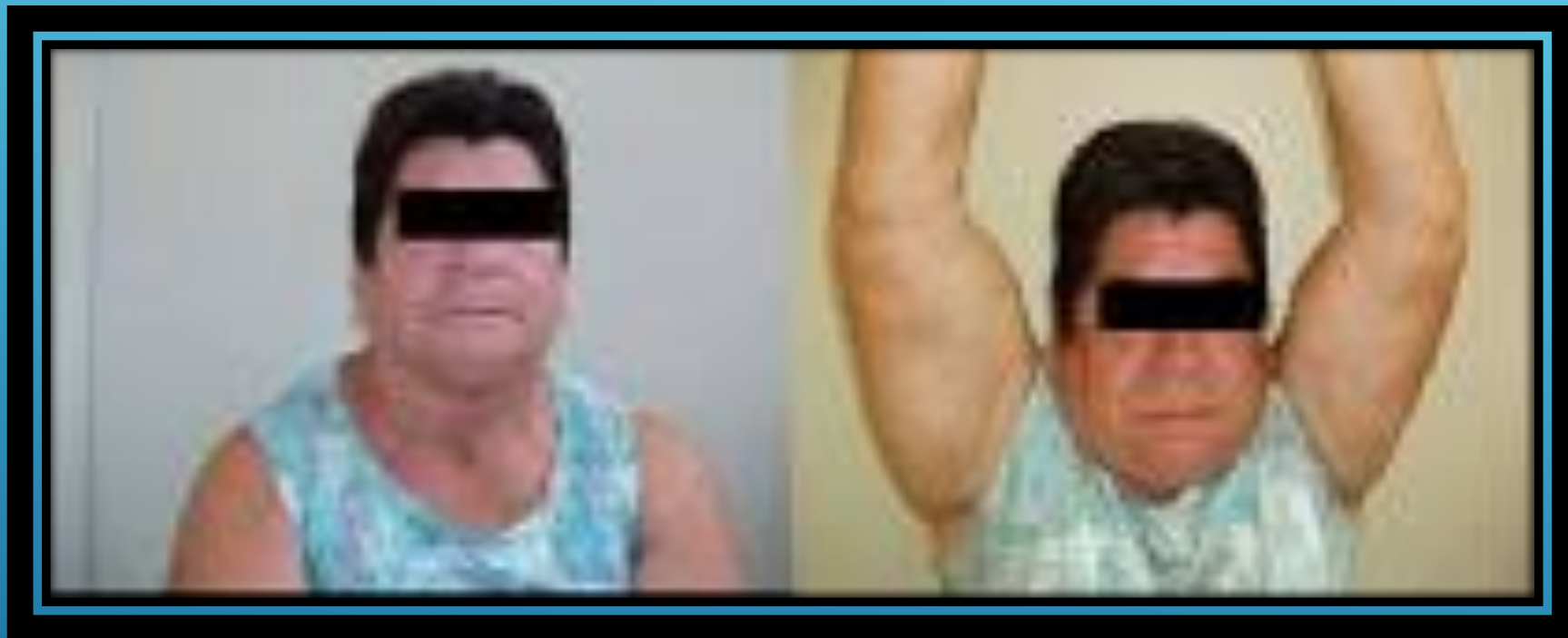**FIGURE 7.26**  
Pemberton's sign

Reproduced, with permission, from McGee S, Evidence-Based Physical Diagnosis, 2nd edn, Philadelphia: Saunders, 2007: Fig 22-6.

# MANOBRA

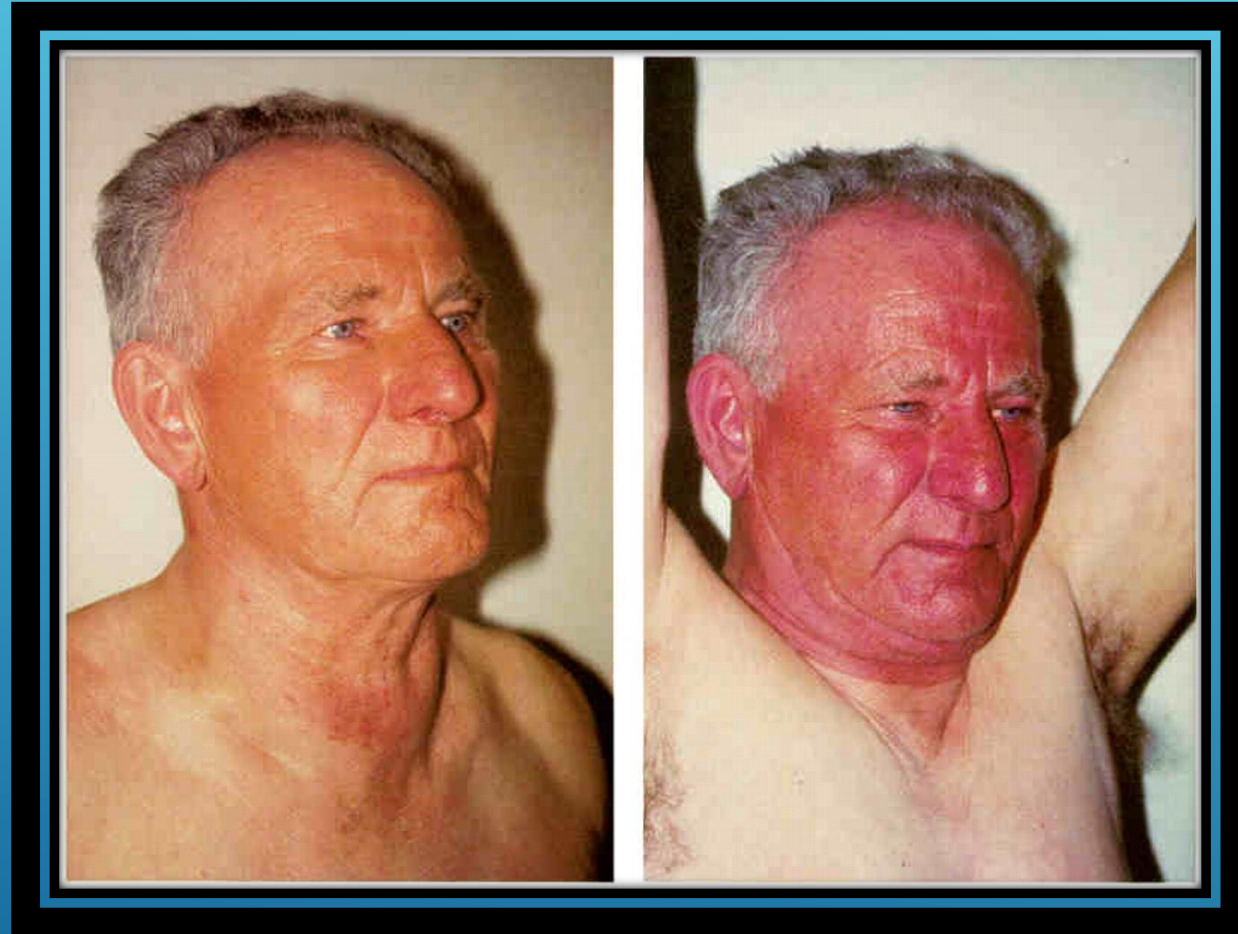- ▶ **Elevação simultânea dos braços acima da cabeça por 1 minuto.**
- ▶ **Se positiva- paciente ficará com distensão das veias do pescoço, plethora facial, dispnéia, cianose e até estridor.**
- ▶ **Indica obstrução da entrada do tórax.**
- ▶ **Bócio retroesternal é a principal causa.**
- ▶ **Outras:**
  - ▶ **Tumores de ápice pulmonar.**
  - ▶ **Linfoma**
  - ▶ **Timoma**
  - ▶ **Aneurismas da aorta.**

# SINAL DE PEMBERTON



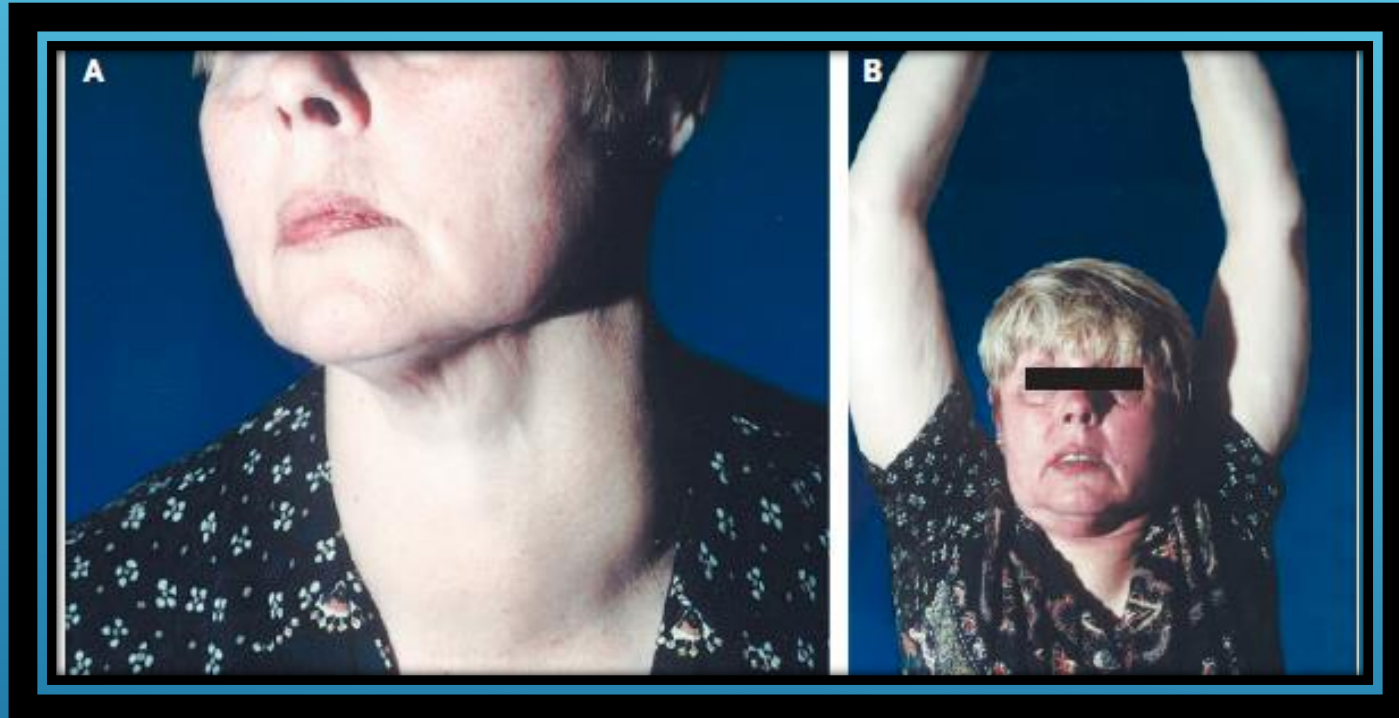Medicina, Ribeirão Preto, 40 (1): 72-77, jan./mar. 2007

# SINAL DE PEMBERTON



[gesepfepar.blogspot.com](http://gesepfepar.blogspot.com)

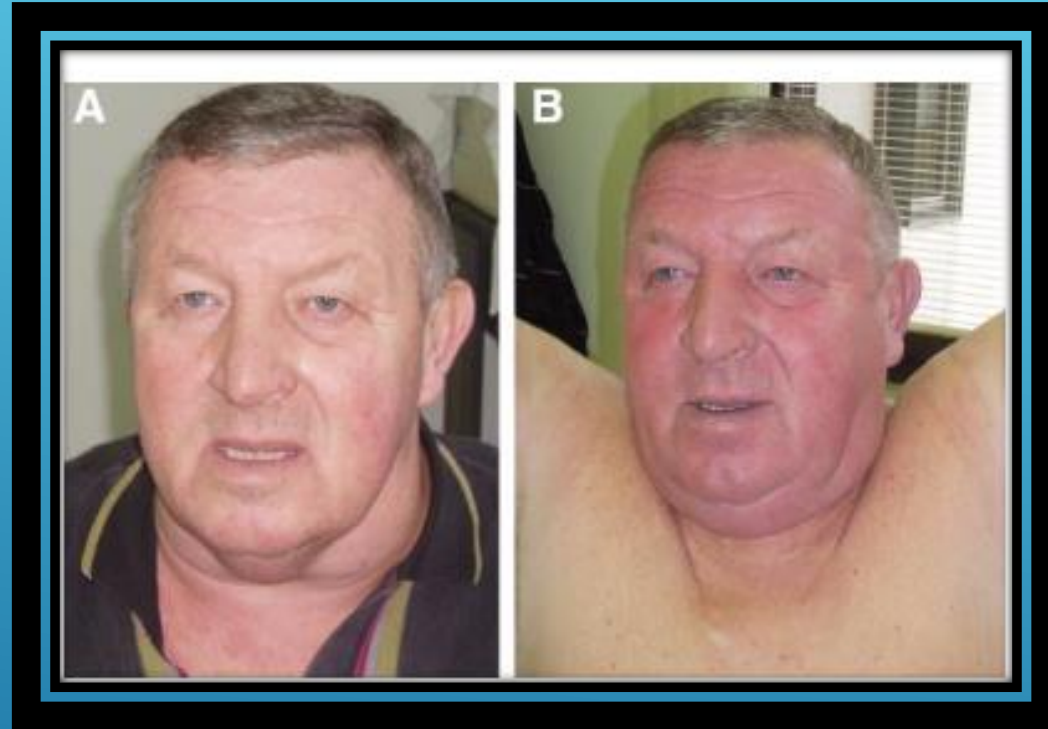# SINAL DE PEMBERTON



The New Engl j med 350;13 [www.nejm.org](http://www.nejm.org) march 25, 2004



# SINAL DE PEMBERTON



The Journal of Clinical Endocrinology and Metabolism (Impact Factor: 6.21). 09/2010; 95(9):4175. DOI: 10.1210/jc.2010-0944

# BIBLIOGRAFIA

- ▶ Maciel LMZ. Thyroid Exam. Medicina (Ribeirão Preto) 2007; 40 (1): 72-77
- ▶ Harrison, 18º edição
- ▶ <https://youtu.be/r1dkasbE7v8>
- ▶ <http://press.endocrine.org/doi/pdf/10.1210/jc.2013-4240>
- ▶ <http://www.nejm.org/doi/full/10.1056/NEJMicm990287>